

DENTAVANTGART

labline

VOLUME III, ISSUE #03 AUTUMN, 2013.

THE MYTH

**WILLI
GELLER**

THE CRAZY ONES:
JOSHUA POLANSKY,
FECHMI HOUSEIN,
THOMAS SING,
SÉBASTIEN MOSCONI,
GUILLAUME
SABATHIER

DISCONNECT

DR. GIL TIRLET,
HÉLÈNE NIZARD-
CRESCENZO,
DIDIER CRESCENZO

**ESTHETICAL
ANALYSIS**

MITSUTAKA
FUKUSHIMA

**COLOR
MATCHING,
MY HOBBY**





SOLUTION OF A PARTIALLY EDENTULOUS CASE WITH THE USE OF A FIXED PROSTHESIS AND ATTRACTIVE GLASS ABUTMENT SYSTEM

Restorative and prosthetic dentistry is increasingly heading in the direction of restorative treatment plans involving minimally invasive procedures.

Under the influence of the media (magazines, television, the Internet), ordinary people are becoming more aware of the concepts of health and well-being, which now and in the future will reinforce a dentistry oriented toward the culture of a beautiful smile, its preservation through awareness of “preventodontia”, as well as restoration of the smile if it has been lost, with a strong tendency towards maximum preservation of the hard and soft tissues of our dental apparatus. The condition of partial edentulism, defined as the loss of a number of dental

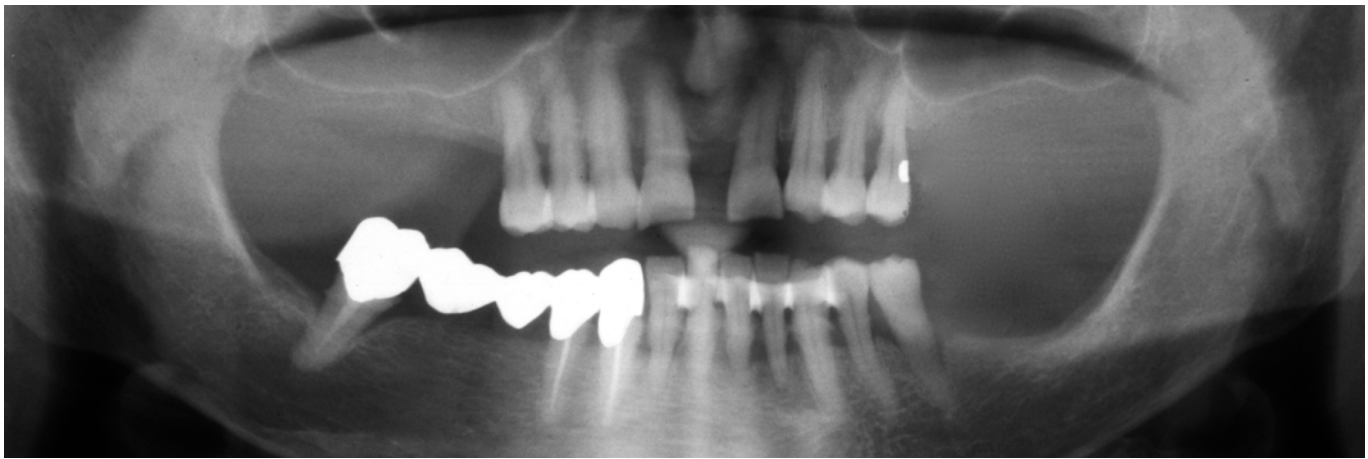elements especially in the posterior area, has always been a problem with regard to fixed prosthetic rehabilitation of our patients. Wherever possible we try to avoid encumbering the intact remaining teeth with crowns and bridges, but we devise rehabilitative treatment plans aimed at maintaining the structural integrity of the remaining natural teeth without any prosthetic accretions but just by using orthodontic adjustments.

From this point of view, implantology has made a great contribution to this therapeutic approach because it allows restoration of the partial edentulism to be achieved without the need for involvement of the remaining teeth in the restoration.



It must be considered, however, that there are not a few anatomical situations where the insertion of implants can be critical, especially in the posterior region, for lack of atrophic alveolar ridges; these clinical situations often require challenging surgery, with vertical and horizontal bone regeneration, maxillary sinus lift, or other complex surgical procedures. It must likewise not be forgotten that there are frequent contraindications to the use of surgical techniques, such as the advanced age of patients, systemic diseases, or simply psychological aversion of patients towards implantology.

In order to achieve the objective of fixed prosthetic rehabilitation, a technique based on the use of Attractive Glass Abutment System may be used in selected cases (ZX-27, HypoDent International sro, www.zx-27.com). This technique takes the opportunity to spread the functional load not only over the periodontal support of residual teeth but also over the edentulous ridge. These are in fact mucosa-supported abutments, made of an extremely bio-compatible glassy material and with no contraindications against underlying hard and soft tissue, individually constructed using an exclusive thermo-moulding technique.



Reported below is a case of partial edentulism treated with a metal-ceramic fixed prosthesis supported by natural elements as well as by three bio-glass abutments used in the upper left and right and lower left posterior areas.

The patient, a woman of 67, had been treated with bisphosphonate drugs by mouth for several years due to problems related to osteoporosis. She came to our attention complaining of chewing difficulties due to the absence of the upper molars and several premolars and lower molars, partially replaced by a bridge thanks to a distal abutment in molar area 47 (**photo 1**). The patient also complained of tenderness in the upper distal premolars and element 35, which she felt to be mobile.

Despite being well aware of her edentulism, the patient asked us to resolve her situation by avoiding the use of removable dentures to restore her missing teeth. She also expressed a strongly negative propensity to surgery and invasive procedures, which therefore had to be dispensed with.

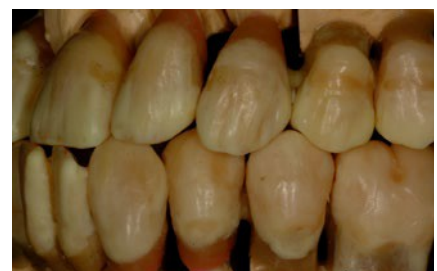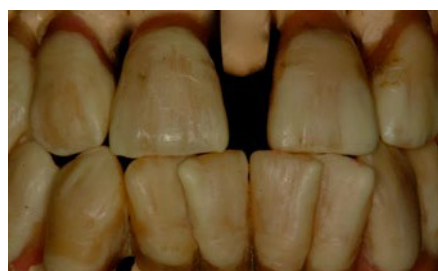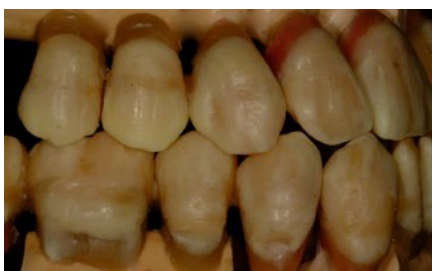Clinical and radiological analysis highlighted a loss of bone support resulting from severe/advanced periodontal disease around the lower incisors and upper last bicuspid of the left and right, as well as the lower left second premolar which is 6–7 mm high to the touch, and with signs of trauma from occlusion.

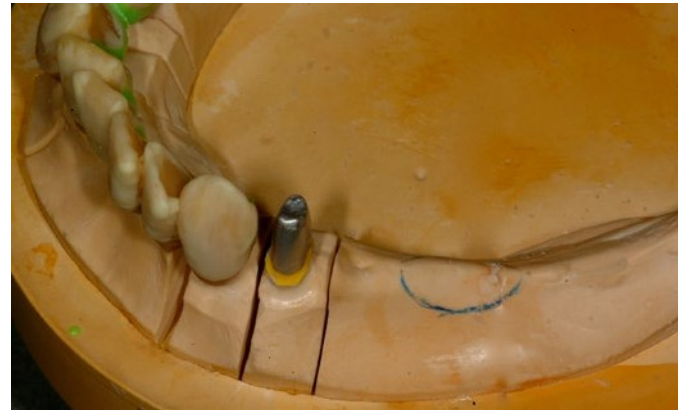
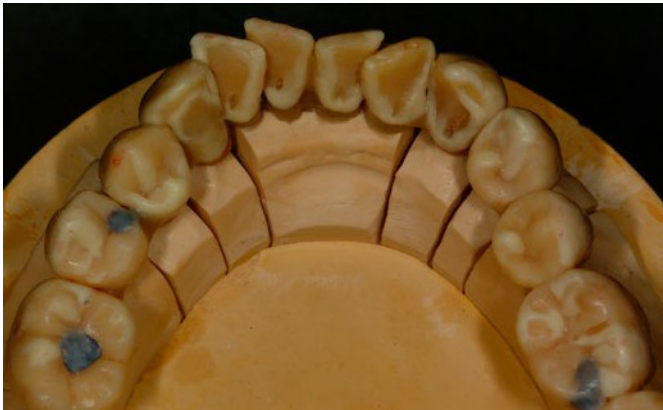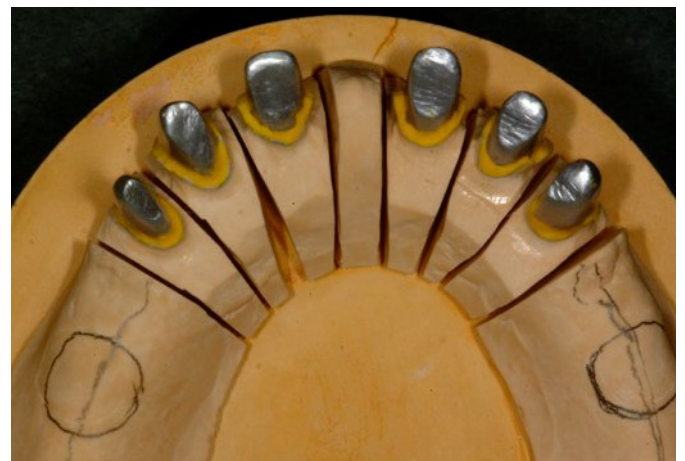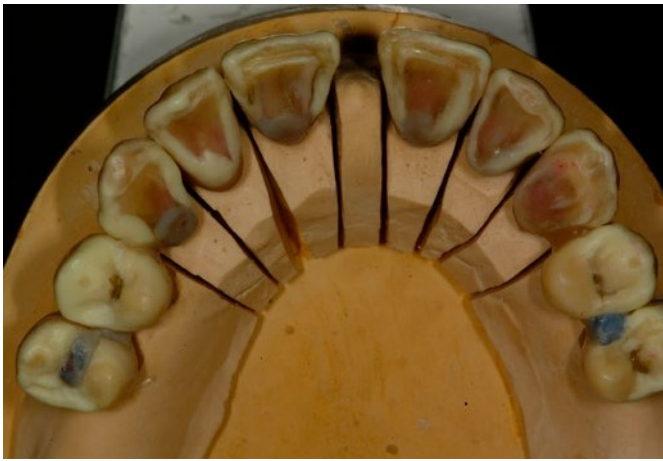There was also mild / moderate loss of periodontal support to the other residual elements, but the conformation of the edentulous alveolar crest was good, especially in the upper right and left.

A large inter-incisor diastema was also noted, probably determined by the agenesis of both upper lateral incisors with distal migration of the two central incisors and mesial migration of the canines and premolars, although a good axis was maintained.

The 4 lower incisors and the more distal premolars 15, 25 and 35 were judged to be unrecoverable, and therefore to be extracted. The other residual dental elements were judged recoverable through non-surgical periodontal therapy based on scaling and root planing, and considered to be valid abutments for the support of a fixed metal-ceramic prosthesis.

The diagnostic set-up performed with a full wax-up (**photos 2–4**) highlighted that the median diastema could not be closed by means of fixed prosthetic locking of the upper teeth, for obvious aesthetic reasons. However, a conventional fixed prosthetic solution would only allow the placement of a single cantilevered element distal to the first upper premolar area (though in the upper canine position), and a distal single cantilever element in the lower left quadrant. A solution like this cannot be considered acceptable from a functional point of view, because the arches would be shortened too much.

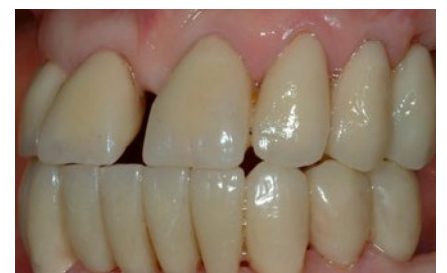
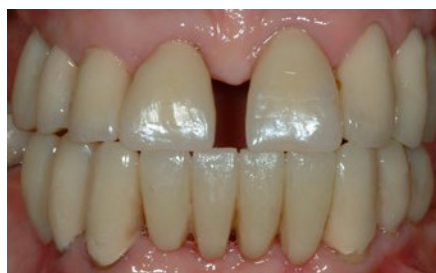
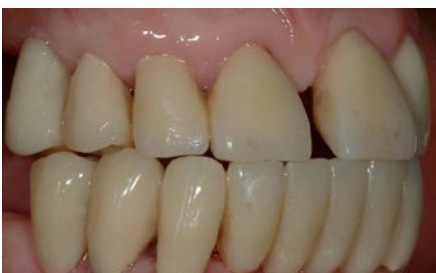
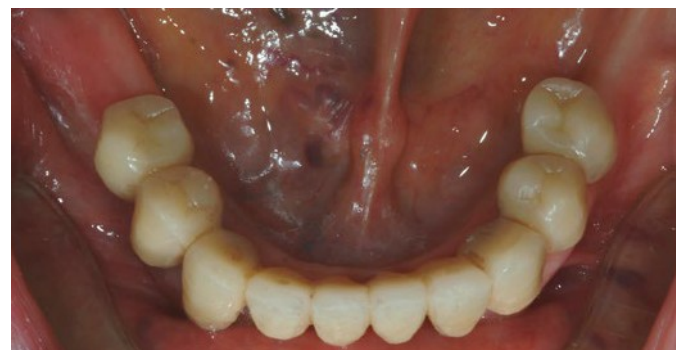
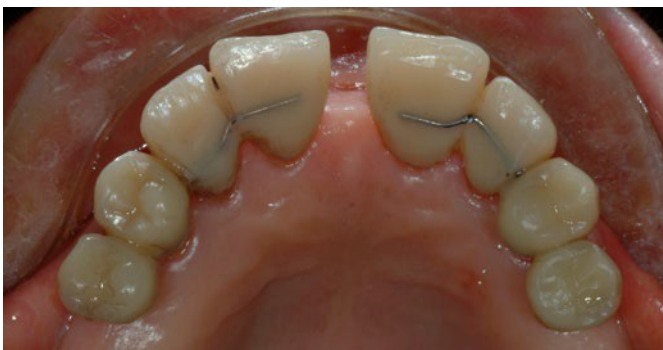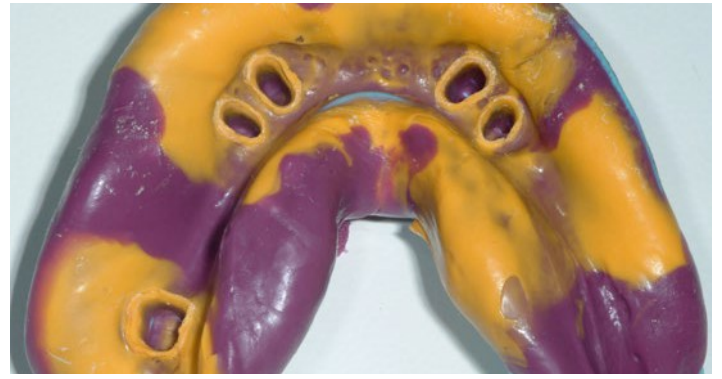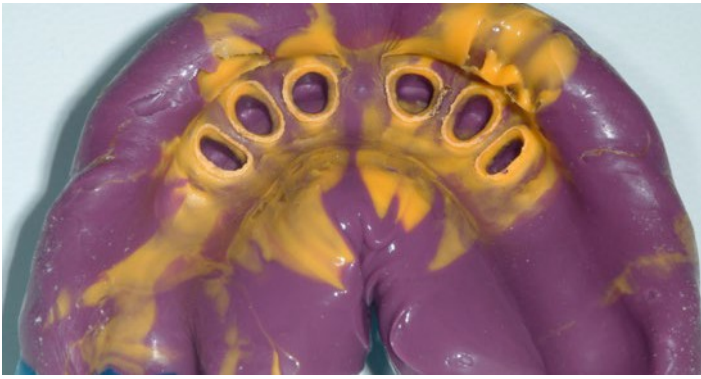The case study therefore led us to design the placement of two ZX-27 Attractive Glass Abutment in the area distal to the extraction of both maxillary second premolars of the left and right sides, as well as a ZX-27 Attractive Glass Abutment in the lower left first molar area (photos 5–8). This option allows us to extend the upper fixed prosthetic design up to the second premolar on both right and left, as well as to extend up to the first molar on the left in the lower mandible and, thanks to the recovery of the most distal abutment, up to the second lower molar on the right.

The irremediable teeth were therefore extracted and a provisional fixed prosthesis prepared anchoring on residual dental elements of the upper and lower jaws (photos 9–13).

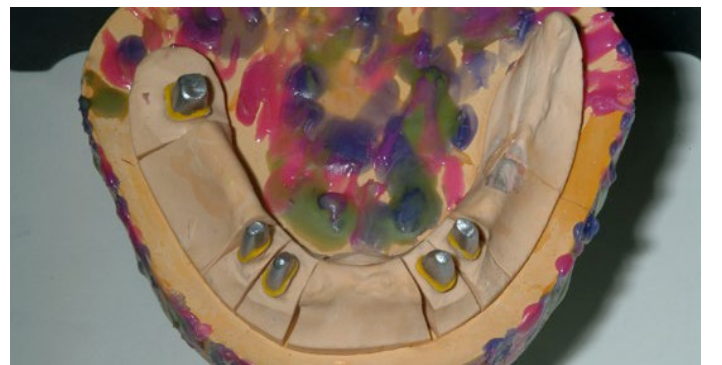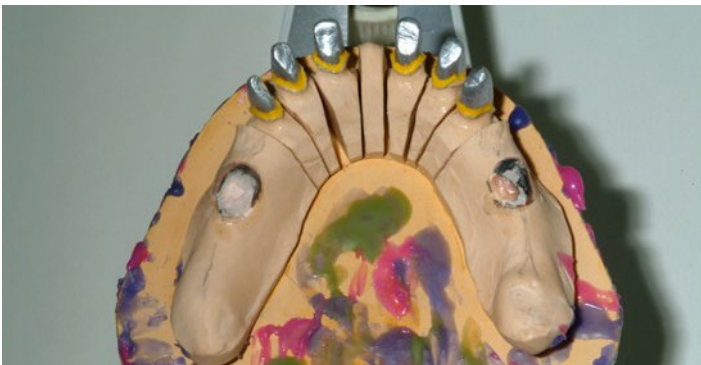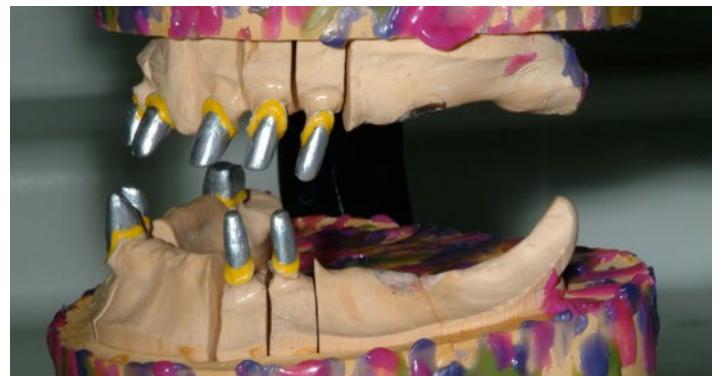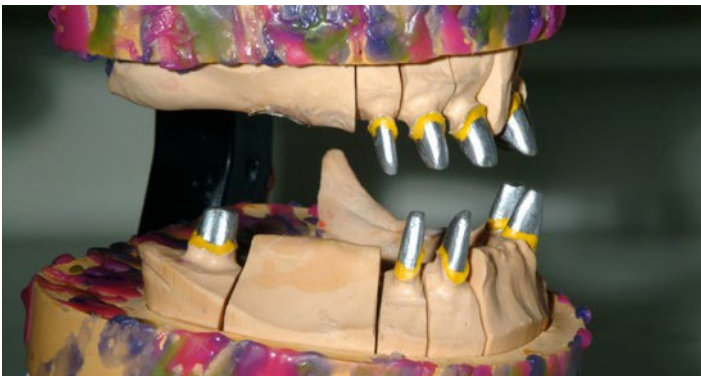During the healing phase following extraction we proceeded with scaling and root planing for the purpose of improving the periodontal health of the dental elements.

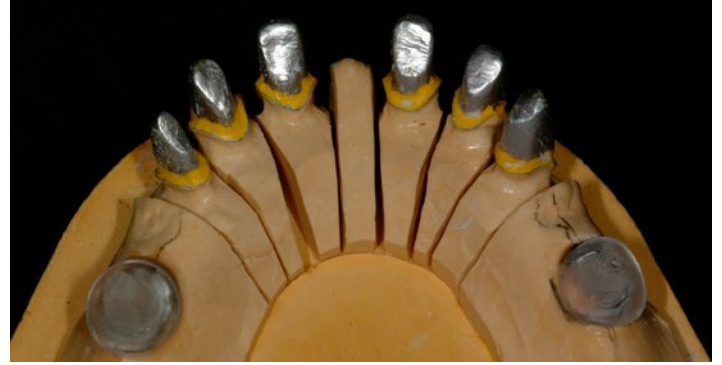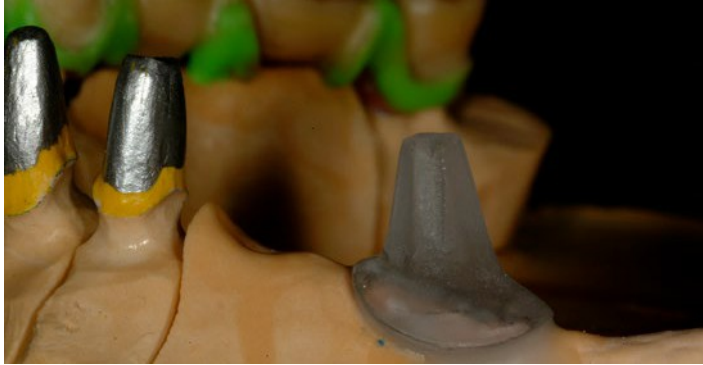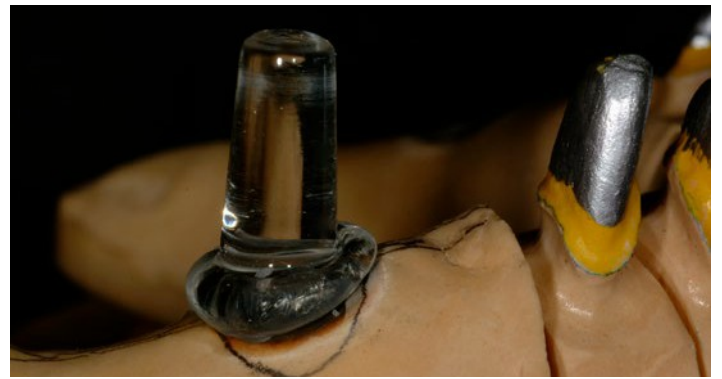
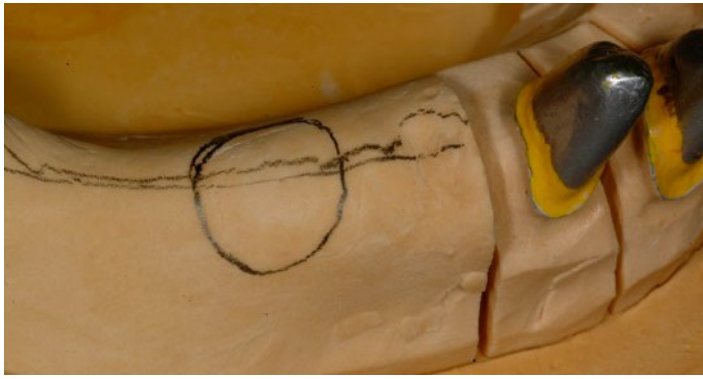




After waiting for about four months, and allowing conditioning of the soft tissues with the provisionals, we proceeded to define the final line of the pillars and then took upper and lower impressions (**photos 14 and 15**). The margins were finished off with a narrow chamfer. The impressions were taken in a vinyl-polysiloxane material using a bi-phasic single-impression technique, after treating the sulcus with a double retraction cord.

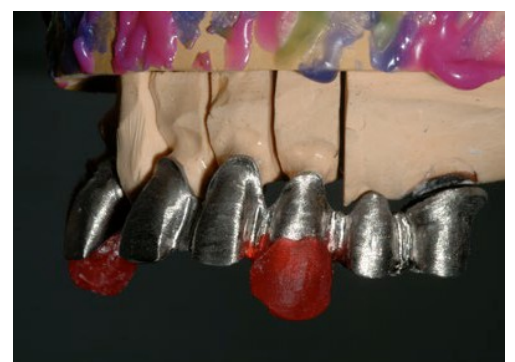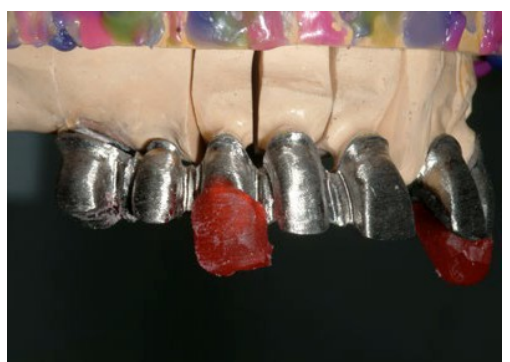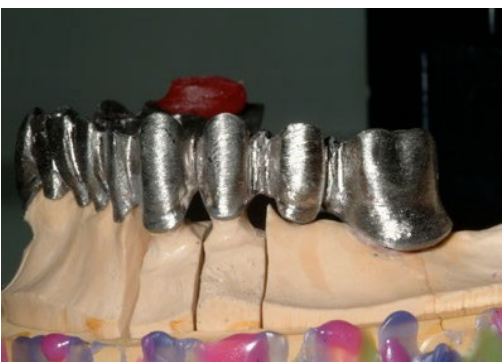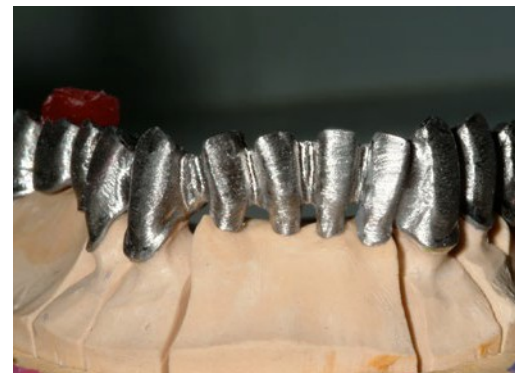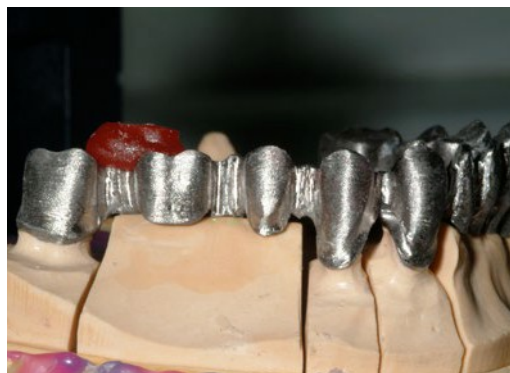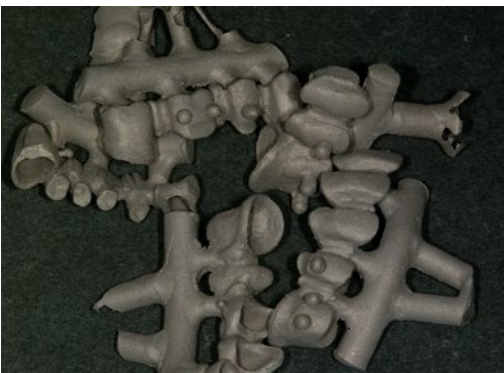In **pictures 16–19**, the master models developed in type IV gypsum and separated by removable dies can be seen mounted on the articulator. The full wax-up enabled the volumes of the teeth to be determined, and then the moulding areas for the ZX-27 Attractive Glass Abutment.





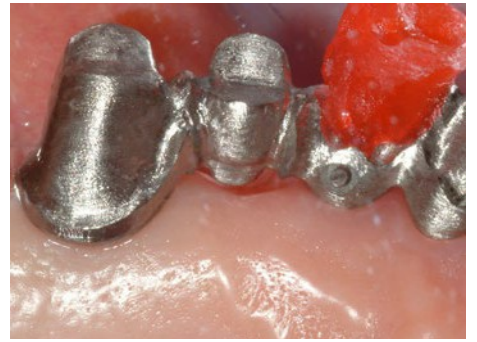
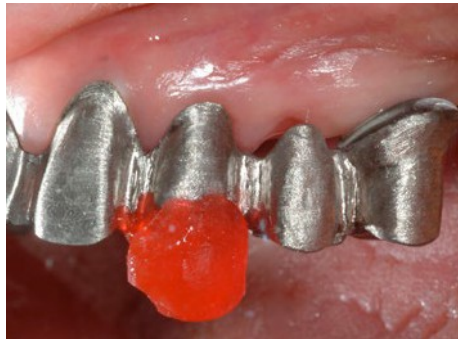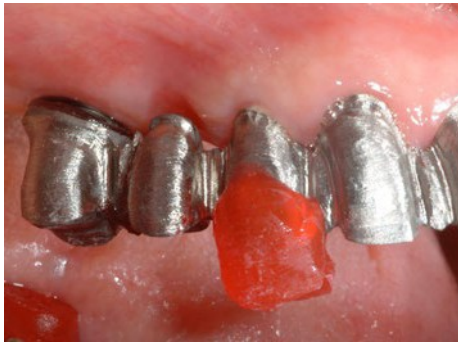In **photos 20–23**, various stages of the moulding and finishing of the ZX-27 Attractive Glass Abutment can be seen.

The new abutments were then fixed on the model, treated like any other dies, and then waxed for the construction of the wax framework to be submitted for casting. Castings were produced in noble metal at 500/1000, and then adapted to the model as shown in **photos 24–29**;

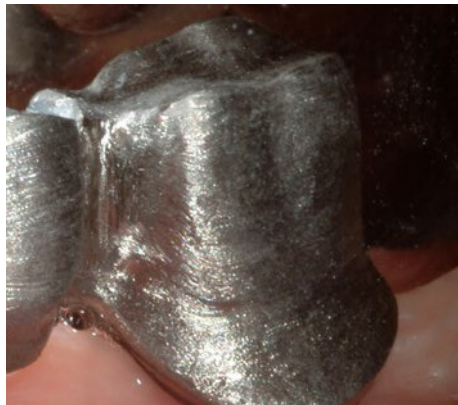
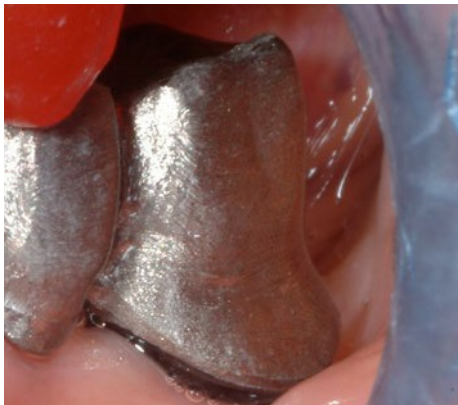


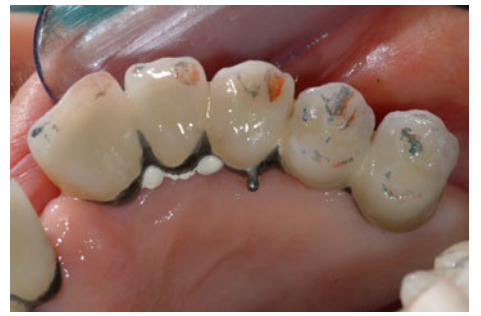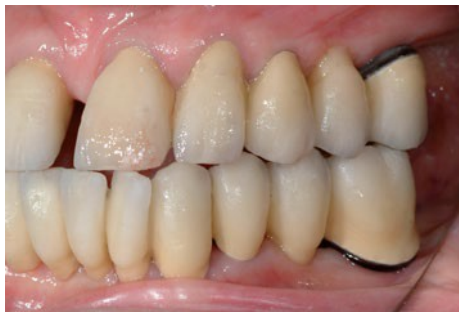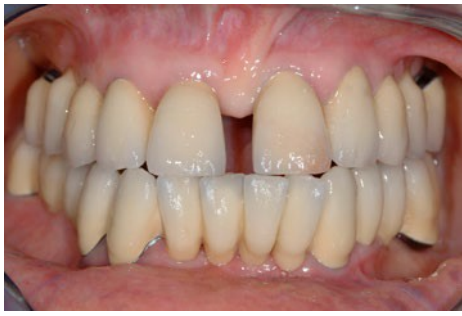The ZX-27 Attractive Glass Abutment were finished as regards their axial walls and height, whilst they were not modified at all in their interface with the edentulous ridge (**photos 30–31**).



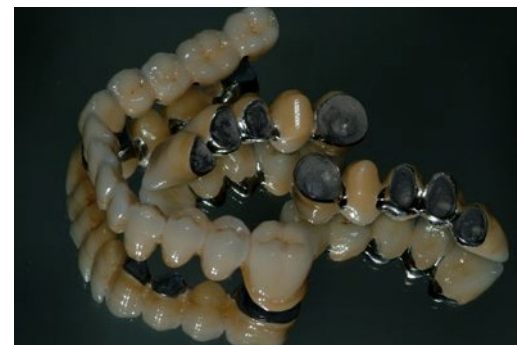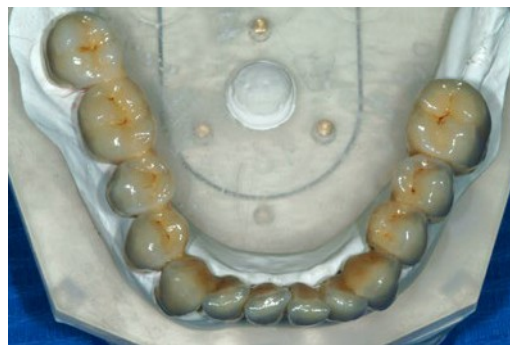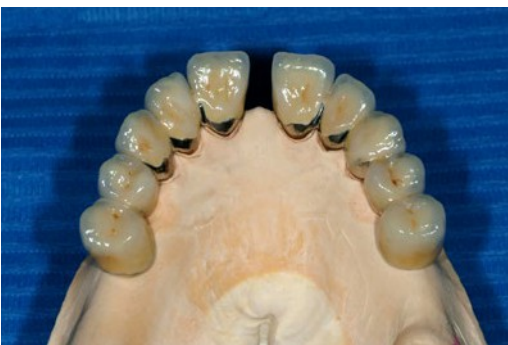The metal frameworks, including the ZX-27 Attractive Glass Abutment, were then sent for check- ing in the patient's mouth; the good fit of the prosthetic structures can be observed, as well as the slight compression of the mucosa support by the ZX-27 Attractive Glass Abutment, detectable by the slight whitening of the ischemic mucosa (**photos 32–34**).



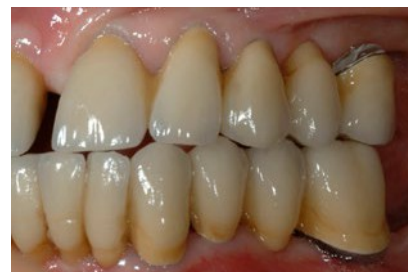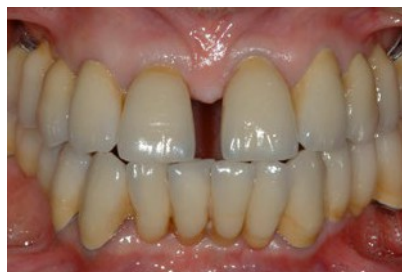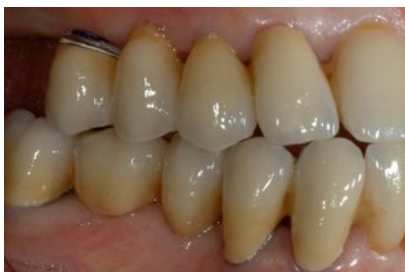◀ This slight compression must always be looked for during the check-in test, as it confirms the correct functional thrust of the ZX-27 Attractive Glass Abutment towards the bone support of the edentulous ridge. Some images of the lower arch too, where is possible to see bubbles of saliva that are formed around the ZX-27 Attractive Glass Abutment and the typical "pumping effect" that is really caused by the pressure of the abutments on the mucosa (**photos 35–36**).



The work, therefore, now back in the lab for the next phase, involving firing the ceramics. In **photos 37–39**, taken during the “bisquit” try-in, some stages in the verification of adaptation and occlusal checking of the prosthesis can be seen, as can the large inter-incisal diastema. which has not allowed us to make a cross-arch bridge in the upper jaw, much more efficient from a biomechanical point of view. Note also the occlusal compromise with the front teeth in a “head to head” ratio because of a third class maxillo-mandibular relationship.

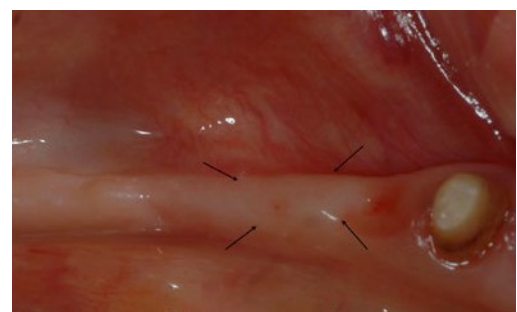
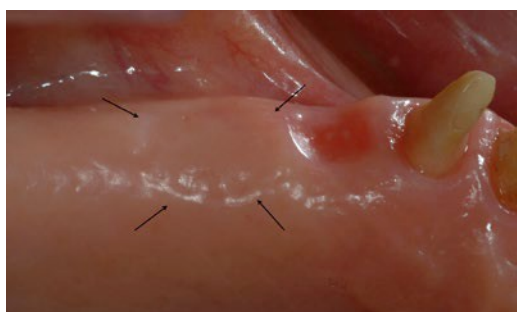
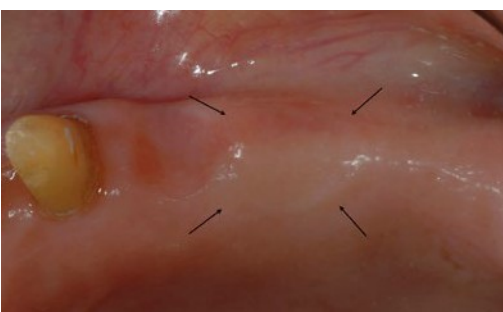


The prosthetic structures were then sent back to the lab for final polishing and glazing (**photos 40–42**).

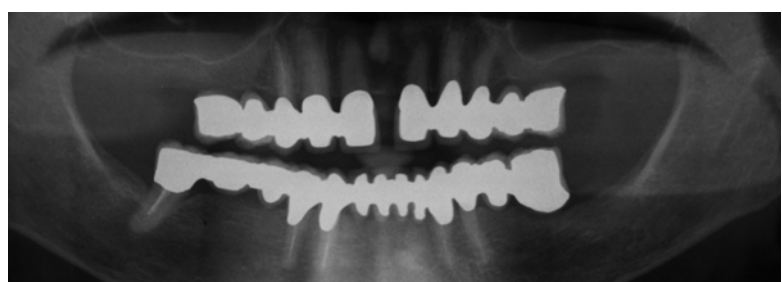
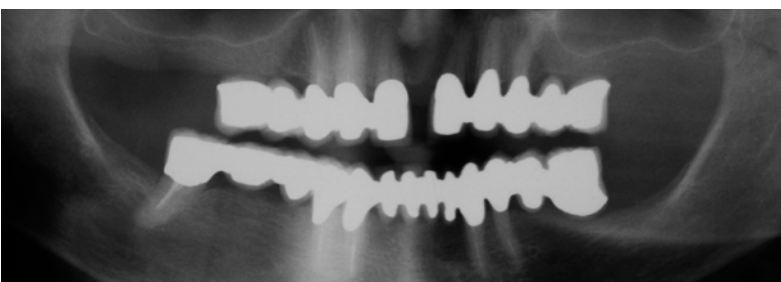


The prosthetic devices were then placed in the mouth. There are two metal-ceramic bridges in the upper arch and a single metal-ceramic bridge in the lower jaw. The ZX-27 Attractive Glass Abutment will be cemented to the bridges and the bridges to the natural elements using glass-ionomer cement reinforced with resin.

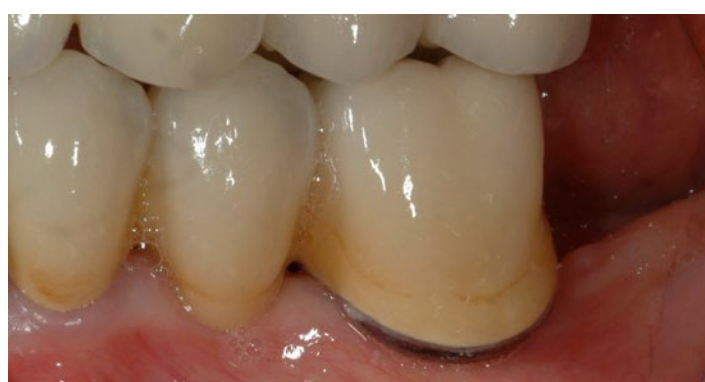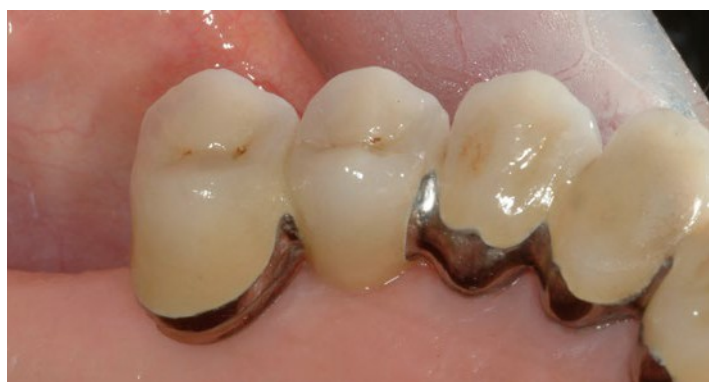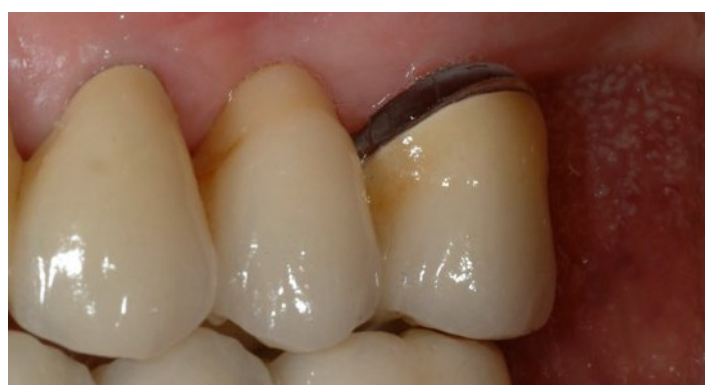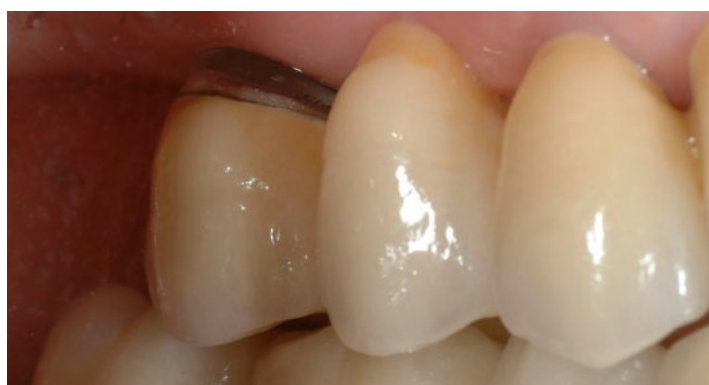In **pictures 43–45**, the result of the finished work can be seen, immediately after placement in the patient's mouth using temporary cement.

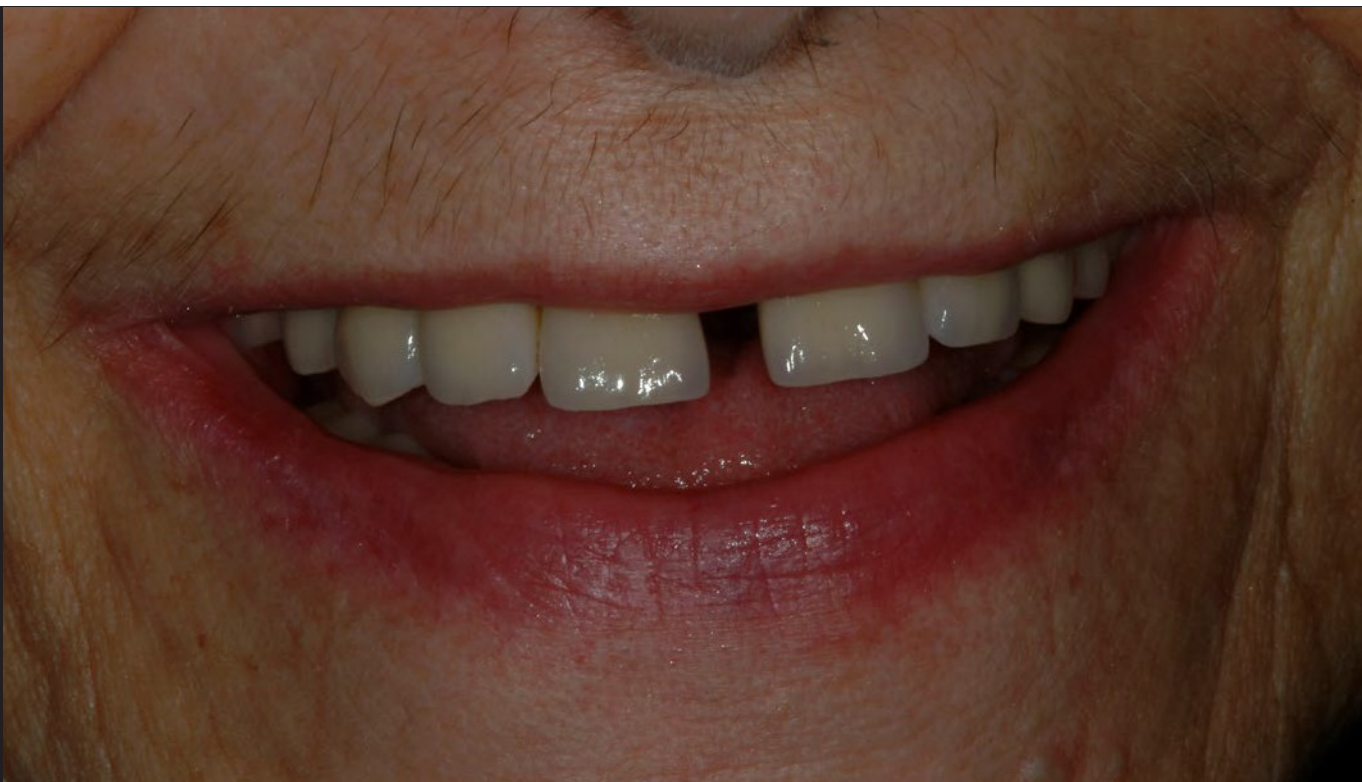

In the pictures taken three weeks later when the final cementation was performed (**photos 46-48**), the extraordinary response of the mucosal tissue below the ZX-27 Attractive Glass Abutment can be seen, with no signs of suffering or inflammation, but if anything, toning from functional load.



The OPG check-up performed 3 years later (**photo 50**), when compared with that taken at the end of treatment (**photo 49**), indicates successful integration of the prosthesis, with a very positive response of the marginal bone around the dental elements and under the ZX-27 Attractive Glass Abutment supports, where not only is there no damage, but we could say In this final sequence of images (**photos 51-56**), taken at 4 years post-op., that over the years there has been re-mineralization of the marginal we control the stability of the tissue under the ZX-27 Attractive Glass periodontal bone. This confirms the excellent soft and hard tissue response Abutment, and the satisfaction of the patient. to the functional load of the prosthesis.





CONCLUSIONS:

Under conditions of partial edentulism implants cannot always be used to restore missing teeth, especially if there are strong contraindications to surgery. In the presence of an adequate number of residual natural teeth, a prosthesis can be designed which is fixed entirely by the use of ZX-27 Attractive Glass Abutment. Thanks to these it is possible to extend the number of prosthetic elements until a normal dimension of the arches is realised.



DR. MIRKO PAOLI

Dr. Mirko Paoli graduated in Dental Technology in 1982. He then graduated in Dentistry from the University of Padua in 1987.

He was Adjunct Professor for the Degree Course in Dentistry in the Department of Prosthodontics at the University of Padua from 1993 to 2000.

He is currently Professor for the Postgraduate Course in "craniomandibular and posture disorders" and for the "Master's in Osseointegrated Implantology" at the University of Padua.

A speaker at national and international congresses, as well as further education courses for colleagues.

Author of numerous publications on the subject of prosthodontics and clinical gnathology.

His practice focuses on aesthetics, dental prostheses on natural teeth and on implants, as well as the treatment of problems of the temporomandibular joint.



ODT. ROBERTO FABRIS

A Graduate in Dental Technology, he has run a Dental Lab in Padua (Italy) since 1990. Specialises in aesthetic prosthesis on implants in cooperation with Dentsply Implants.

Devotes much of his time to staff training courses and lectures

in Italy and abroad, a speaker in numerous courses and conferences.

Collaborates with GC as a speaker in courses on the INITIAL ceramic and Gradi a composite.

In 2005 he began to deal with prosthetic cases

through the use of ZX-27 bioglass abutment; he is an Italian national referee in training courses and qualifications requiring the use of this system.



labline

www.lablinemagazine.com



facebook

[www.facebook.com/
lablinemagazine](https://www.facebook.com/lablinemagazine)



DentAvantgArt

9400 Sopron, Virágvölgyi u. 59.
www.dentavantgart.hu
info@dentavantgart.hu