

There is new under the sun....

Laszlo Nemeth dental technician master, DentAvantgArt Division, Sopron, Hungary

Tooth gaps disrupt perfect closure and chewing harmony. Their effect on human organism are known. Tooth gaps can be eliminated by fix denture when adequate numbered and situated own teeth are present. In case of a low number or unsuitable teeth prosthetics are applied. Their disadvantages are known. In certain parts of such cases application of implants remains a possibility, that is a rather complicated intervention and raises several problems. Despite of successful construction, success is only partial, as with solving one problem, an other, hardly curable problem brings to surface, namely the patient's damaged psyche. Accomplishment of one or two end situations had been studied for a long time by professional researchers. The essence of ZX-27 Attractive Glass Abutment System is, that those who still have own teeth, but do not want prosthetics or implants can obtain fix dentures with this method.

Condition of introduction and application of a long last designed denture is that implantation should not be resulted in permanent and irreversible tissue damage. Secondary changes within the implant, that could cause alteration on the structure of the surface or modification of element composition due to solubility of the saliva, that is dissolution of substances from the glass should not occur.

Why the glass?

It was a long way to ZX-27 Attractive Glass Abutment System. As follows we can look into why the materials on trial did not work.




Fig.1. Heat modeling of general glass.

it. Following the trial of many experimental glas-

polished while as a result of them it looses as much from accuracy that it did not live up to expectations, stub will not fit to the gum with whole surface. Things are the same with plastics, similarly the processing causes trouble. Moreover plastics are porous that causes food deposition then inflammation. Furthermore most part of commercial plastics are not flexible enough and are not thermal resistant. In case of glass ceramics and ceramics, shrinkage after adaptation to the gum is problematic, furthermore these are not really self cleaning because of porosity. General glasses also did not equal expectation, the causes will be mentioned later. After the trial of the mentioned materials, there was only one choice, namely the glass and a special composition within

In case of metals casted stub has to be processed,

ses, ZX-27 glass served the listed view points.

Main characteristics of ZX-27 glass

General glasses did not equal expectation as dental glasses have to serve many view points at the same time, namely:

- meltability
- workability
- rigidity
- chemical resistance

There is no such amongst general glasses, the main problem is meltability and chemical resistance. General glasses can not be heat-processed under dental technical circumstances. It can be fractured during heating or invisible hair-crack may develop that leads to fracture. Similar processes occur with cooling. Chemical resistance is the other problem. Saliva interacts the glass and evokes chemical reaction sooner or later. Meanwhile toxic substances, like plumb and barium get into the saliva from the glass. These substances are harmful to the human organism.

Conditions made on the utilizable glass:

- workability
- rigidity suitable to utilization
- chemical resistance and

its effect on organism.
 Main characteristics of ZX-27:
 (a) Melting temperature: 1560-1600 °C
 (b) Pressure strength: 120-150 Mpa/kp/mm²
 (c) Acid resistance: Hydrolytic Class 1.
 (d) Alkaline solubility: Hydrolytic Class 2.

In addition to its main components ZX-27 contains small amount of zinc and magnesium but does not contain harmful plumb or barium that can be found in general glass and their raw materials. Good workability of ZX-27 glass under laboratory circumstances is own to its high boron-tri-oxide content. That made the otherwise indispensable high alkaline content being reducible. Due to the low sodium content, corrosion does not cause local pH rise nearby the gum. The above assure dental utilization of structural elements made from ZX-27 glass.

Contraindications of this way processed ZX-27 Attractive Glass Abutment System:

- Excessive deep biting
- Loose or shaky mouth works.

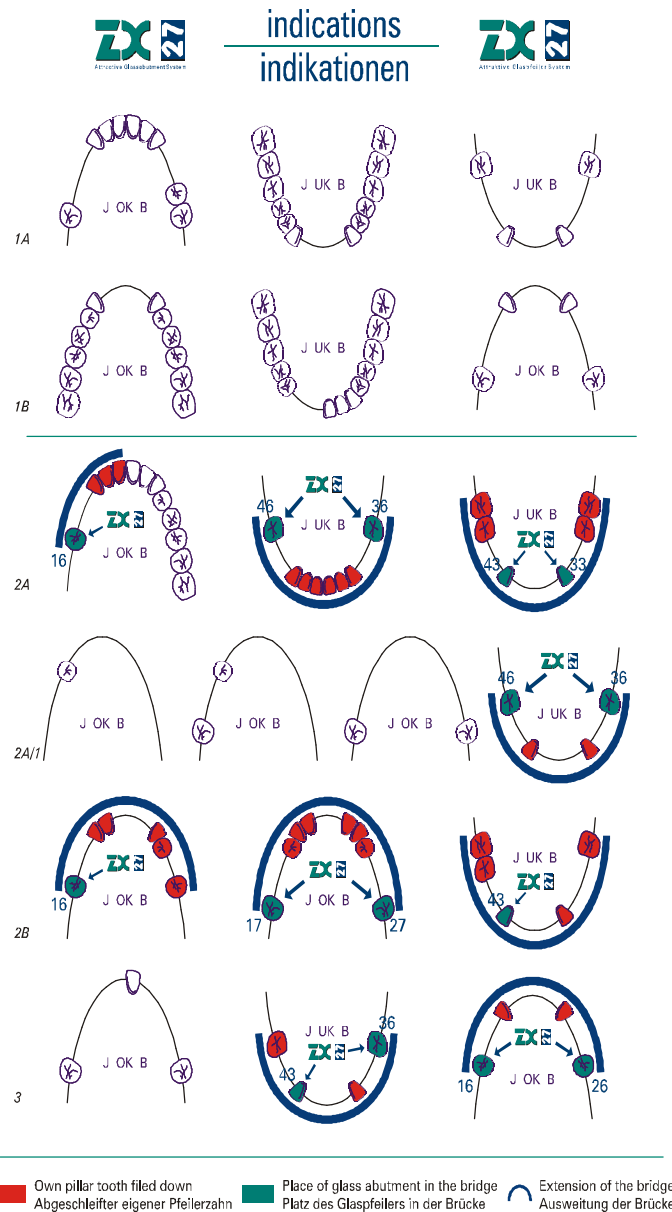
Indications and fields of utilization:

- unilateral status
- bilateral status
- in combination with implants
- supporting arching of large span bridges

Illustrations of indications were born from eleven years' practical experience. Application of the abutment is safe with simultaneous employment of indi-

cations and acquired technology. The last ten years and large number of implantation irrespective of geographic situation have proved, that acceptance of

tant is that general pathological thesis, whereas chronic irritation of non keratinized mucosa leads to development of keratinized mucosal epithelium,



the glass abutment - despite of previous reservation - was undiminished. This is own to its greatness that lies in simplicity and to its increased convenience for the patients. Naturally several unanswered questions have escorted my work thereafter the start ten years ago. The first and most impor-

tant is that general pathological thesis, whereas chronic irritation of non keratinized mucosa leads to development of keratinized mucosal epithelium,

Pathological studies

Cytological smears from the mouth-wash fluid mainly contained superficial, mature cells. In 17 smears of 3 patients with glass abutment amongst the 67 cytological specimen of 9 patients were found a few keratinized but otherwise typical cell beside the large number of non keratinized epithelial elements (figure 1/a.)

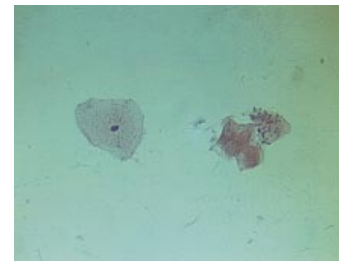


Figure 1/a.

These three patients had bridges supported by two glass abutment built in 2-4 years before. There was no significant keratinization either in the specimens of the other patients with glass abutment supported bridges or in the precipitated mouth-wash fluid of control patients with traditional bridges.

Typical keratinized stratified epithelium was present on the surface of the gum under the glass abutment (figures 2/a and 2/b). Keratinization corresponded to parakeratosis and hyperkeratosis histologically. There were no mitotic figures amongst the epithelial cells, layers of the epithelium presented typical maturation tendency towards the surface (figure 2/a.).

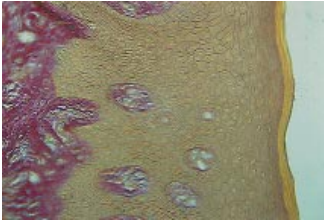


Figure 2/a.

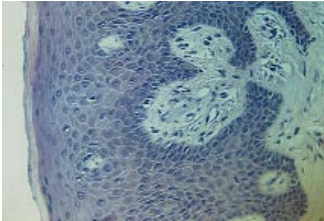


Figure 2/b.

The applied fixative poorly fixed tissue glycogen, however the cytoplasm of the cells contained abundant glycogen (figures 3/a and 3/b)

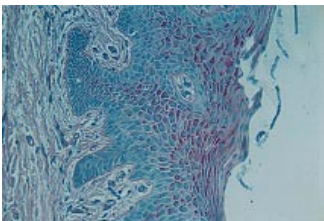


Figure 3/a.

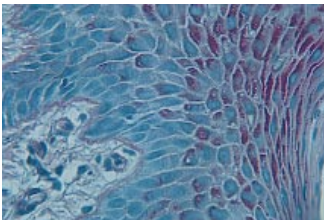


Figure 3/b.

Border of the epithelium and connective tissue was sharp, papillarity was slightly flattened, vascularization was scanty but there was an increased amount of collagen (figure 2/a.). Basal layer of the epithelium showed focal, while the spinocellular layer a diffuse and marked expansion (figures 2/a and 2/b).

In the gingival tissue under the removable prosthetic or without any dentures, that served as control, keratinous tendency was

also noticed, although the keratinized layer seemed to be thinner compared to those under the glass abutment (figure 4.).

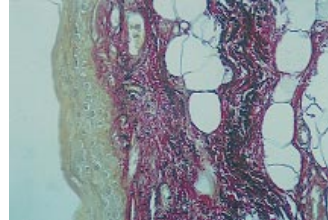


Figure 4.

With scanning electron microscopy the surface of the new abutment at the gingival side was smooth. Scraping, mechanical injury and deformity as subject of mucosal irritation were not found.

Element composition measured at five different sites (within 350 micron in diameter areas) was practically the same. The surface and the chemical composition of the glass abutments implanted as long as eight months and one year equaled that of the new abutments.

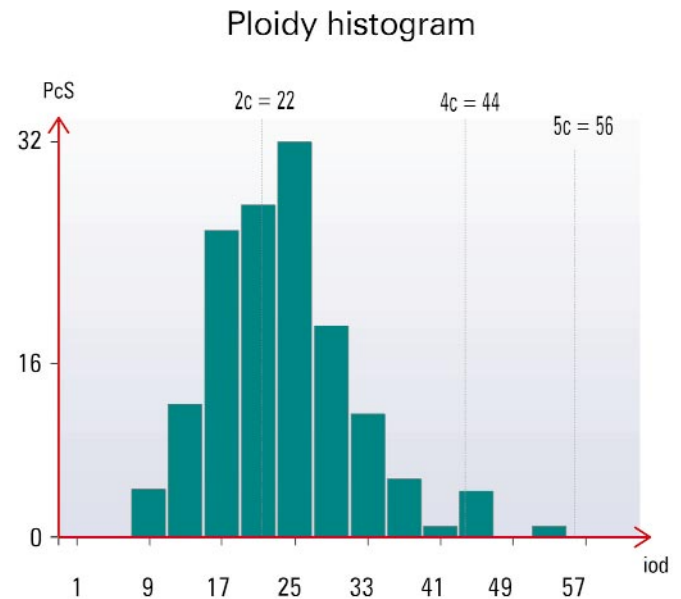
According to the cytological and histological studies it can be established, that the mucosa under the glass abutment showed mild but typical keratinous tendency, that was characterized as hyperkeratosis and parakeratosis and not as dysplasia of the precarcinomatous leukoplakia.

Similarly to the mucosa of those with traditional bridges, removable prosthetics as controls and of those who chew on the gum, histologically there was a harmless, adaptive keratinization. The degree of keratinization was far below that of the leukoplakia noticed due to hot and spicy foods, meantime the cells remained typical. As

a conclusion it can be stated, that cytological and histological changes of the mucosa under the glass abutment are not different in quality (only in quantity) from those noticed under traditional bridges, prosthetics and also from those patients who are without dentures and chew on their gum.

DNA analysis was performed on Feulgen-Schiff specimen with the help of computer assisted histological image analysis program (DNASK). This program is able to determine 13 morpho- and densitometric parameters of the nucleus. The image analysis for DNA measurement within the basal cells of the

DNA analysis is useful in case of such procedure as morphologically completely similar tissue lesions can represent different prognosis if the cellular DNA content changes determined by naked eye or by microscopic examination. These changes can be the result of overloading when the DNA content simply doubles and polyploid, tetraploid cells develop, but when the epithelium displays inclination for dysplastic metaplastic change, that is precancerous stage, the DNA content not only doubles but irregularly changes, thus can be two and a half times or three times, three and a half times more than the normal. The result of DNA



epithelium of the three studied groups (with glass abutments, with removable prosthetics, chewing on the gum) revealed a Gauss curve with a peak within normal diploid DNA range. Number of tetraploid nuclei remained below 4% and aneuploid polyploidy did not occur.

analysis indicated normal diploid tissue appearance in addition to a significantly lower tetraploid cell population, which could be due to mechanical stress, on the other hand we did not find aneuploid polyploidy that characterized precancerous stage (figure 5.). Summarizing the results of pathological studies, inste-

ad of the expected metaplastic, dysplastic changes that were reasonable from our general pathological knowledge, we found simple adaptive **hyperkeratosis** under the glass abutment, the degree of which did **not even reach the degree of hyperkeratosis in patients who chewed on their gum. Glass abutment did not mean such mucosal stress that was caused by the direct gum chewing on the mucosa.**

Static analysis

For the substitution of so called free end situations, employment of removable or anchored or supported bridge works are recommended according to the therapeutic indications accepted by the methodological letters.

Utilization of removable denture is often rendered because of the patients' aversion from such type of prosthetics or because of the biological or financial causes or the patients' fear from the surgical intervention in case of implantation.

The aim of our static analysis was to verify the importance and role of glass abutment in supporting and its function in conducting the consequent forces. Furthermore we wished to contradict the presume that ZX-27 did not at all differ statically or functionally from the practice of free end bridges. The Transient Element method served as tool of the study is suitable for answering the aimed,

conceived and expected questions. It is obvious at first glance from the figures that the greatest importance of the glass abutment in force conduction and driving on supporting teeth is its relief role. (6. kép)

Figure 6. well demonstrates that conduction of the consequent force much better acts on the two supporting teeth due to the glass abutment than in case of free end bridges (Figures 6-7.)

The results of static analysis performed with Transient Element Method

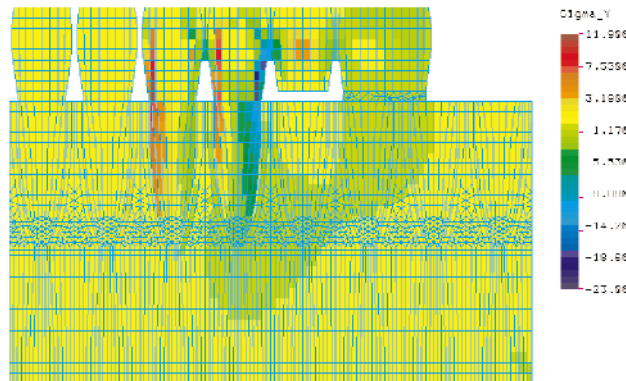


Figure 6. Modeling of perpendicular tensile-pressure potential in case of glass abutment support.

demonstrate that the prosthetic with glass abutment support does not work by the practical and theoretical system of the free end bridges.

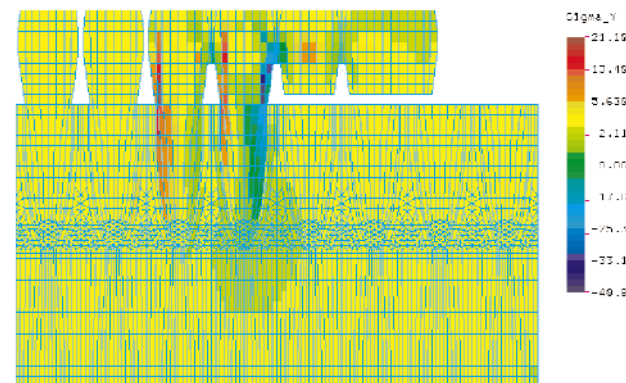


Figure 7. Modeling of perpendicular tensile-pressure potential in case of free end bridge.

Although the data of technical literature were determined by the given data published in most recent worldwide journals and by our measured data, the accuracy of the measures were aggravated by the capacity of the applied PCs or by the simplifications due to the presumably low effect of certain geometric characteristics.

The following results developed:

- gingiva is 2 mm in diameter
- cortical bone is 3-3 mm in diameter

- paradontium along the roote is 0,25 mm in diameter
- thickness of cortical bone is 0.5 mm in diameter

Indication of the remaining data was easier owing to the relatively more simply and accurate measurability of substance specificity. Such specificity are of the metals and ceramics employed during preparation of bridges that are summed in a table expressible by Rugalmassi modules and by a so called Poisson number. Because of missing data in the technical literature and as the continually changing, individually derived, personal characteristics are lacking, measurements may contain inaccuracy, but these results are below the presumed values of real data. It means that oral glass abutment would present better results if we could measure or model them. It so happens that in case of vertical and lateral forces support of concave surfaced glass abutment is more favourable in reality (this is characterized by lower equivalent potential), in contrast to the model calculation of the present plain glass surface (Figures 8-9). Concave surface can transmit a lower proportion of lateral force to the convex gum surface, thus decreasing the lateral bending force of the crown (Figures 10-11). Consequently this study e.g. could not model the effect of pulsating forces on paradental fibers, mucosa-bone bad e.t.c. These effects were supported by further, mainly clinical, longitudinal experiments, that would be the point later. Evaluation of the results were rendered difficult as we could not obtain the documents of such measurements in relation to individual dentures. Here I principally think

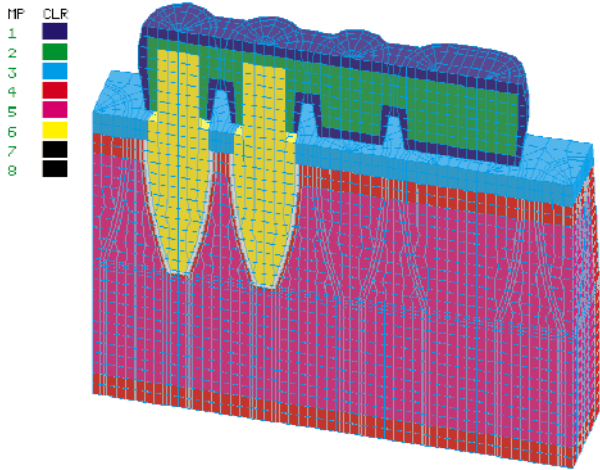


Figure 8. Three dimensional model of free end bridge in longitudinal semisection.

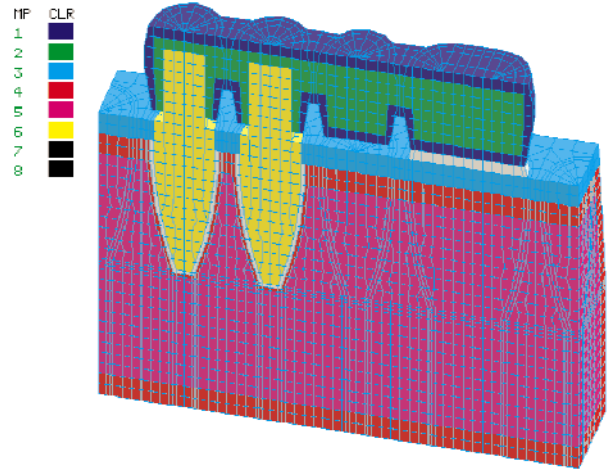


Figure 9. Model of glass abutment supported bridge. Separation of the single layers and the glass is well seen.

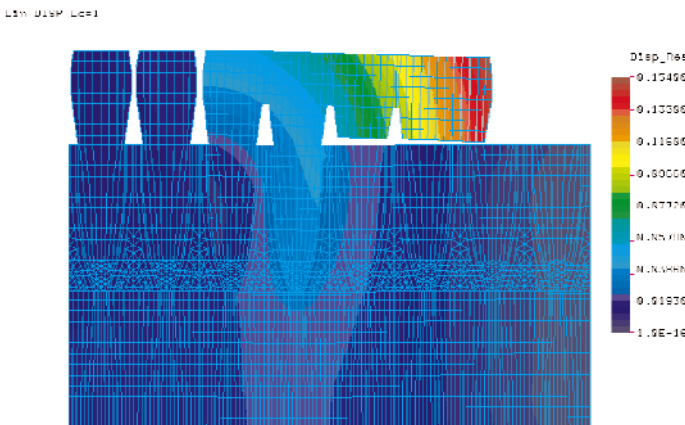


Figure 10. Model of free end bridge force shift in case of 100 N vertical force.

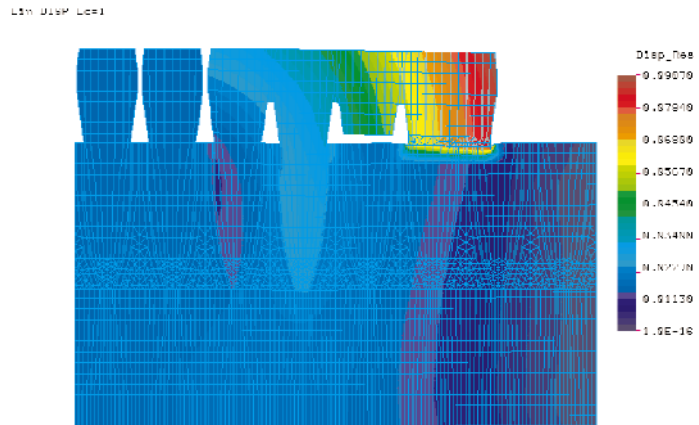


Figure 11. Model of glass abutment supported bridge force shift in case of 100 N vertical force.

of the effect of consequent forces on the paradentium of existing teeth and of the measured results in case of model casted metal plates, partial uni- or bilateral anchoring.

As after the pathological and static examinations, that previously questioned applicability of ZX-27 Attractive Glass Abutment System, had administered reassuring results and chronic toxicity, cytotoxic, genotoxic and biopersistency studies had presented negative results, it became necessary to examine what changes did the long lasting equipment cause on bone bad in contact to the surface.

Radiology

In case of accurate determination of the bone's condition we did not principally use OP pictures employed in dentistry, but we elected to series of CT scan that can measure bone density. Traditional radiological method for examining dental alveolus is the thick layer shot, the so called panorama X-ray. It is extremely useful in designing the denture. It is also employed in examination of localized inflammatory bone resorption. However it is less applicable in quality estimation of the bones'

calcium content and completely inadequate for quantitative determination. That is why we performed computerized layer analysis within as thin layers as possible. With this method we can visualize the bone substance: the outer compact bone substance and the spongy substance beside (Figures 12-13). Densitometry can give indirect information on the calcium content. The question was further rendered difficult as every people had different skeleton that could be altered by the age, sex and way of living. Medical science has not been engaged in alveolar manifestations of osteopo-

rosis. Therefore we can not give absolute results but we measured densitometric values of the surrounding and glass abutment carrying bone. Calcified trabecule and fatty marrow are always present within the measured volume. The former increase, the latter decreases density. The higher density value we measure, the higher is the calcium content. Measurements in the studied patients were performed between 27.06.1996. and 19.10.1999. Axial plain examination of the glass abutment carrying dental bed was performed natively within 1.5 mm in diameter slice thickness, from

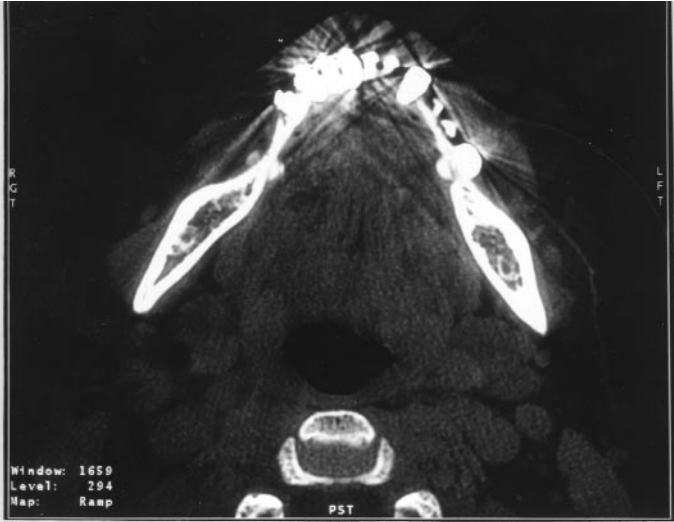


Figure 12. Position of the glass abutment within the mandible.

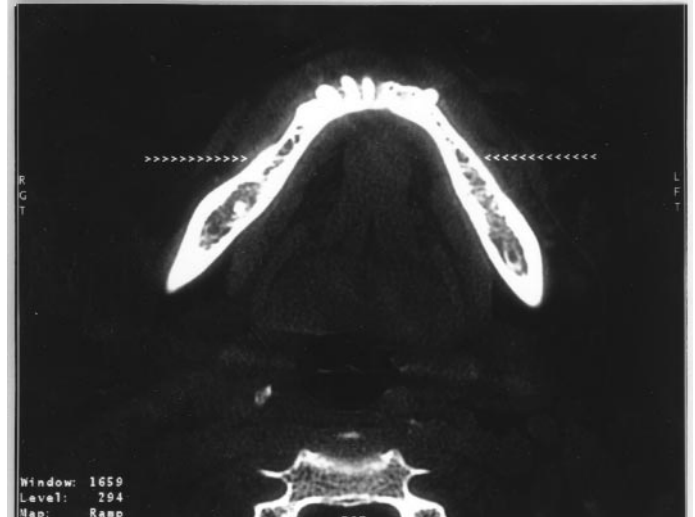


Figure 13. Bone structure beneath the glass abutment.

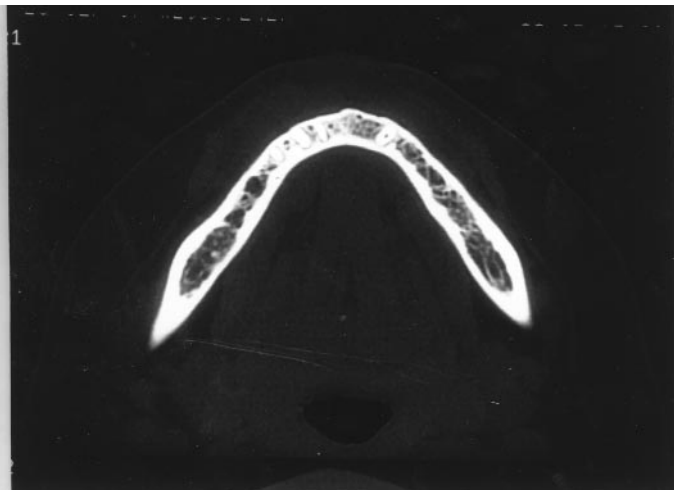


Figure 14. Condition of the bone structure at time of the first investigation, 1 year after oral implantation.

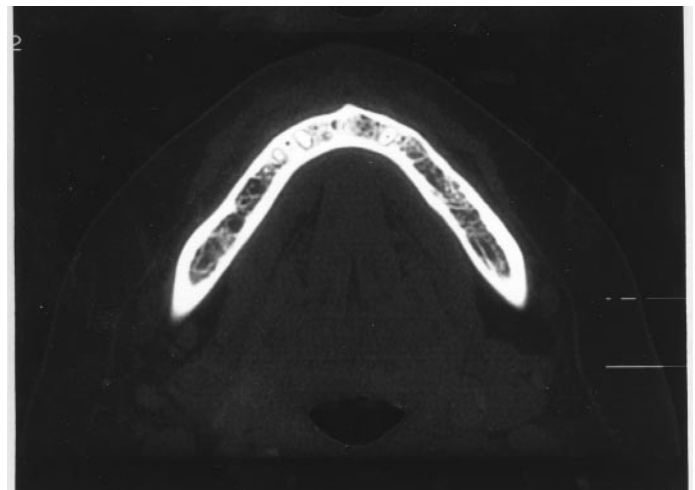


Figure 15. Condition of the bone structure at time of the first investigation, 1 year after oral implantation.

the body of the bridge works along the nearly complete volume of the bone structure. In possession of the measured and calculated data we can tell that ZX-27 does not influence unfavourably the calcium content of the force bearing bone structure despite of its permanent contact with the gingiva, focal calcium loss (bone resorption) does not occur. Just the opposite! Measured values represent local strengthening of the bone (Figures 14-15).

Description:
Glass abutment system can be seen as hyperdense structure on both sides (Figure 12.) beside the lower jaw. Arrows on the picture (Figure 13.) indicate the bone under the glass abutment system. The next two figures (Figures 14-15) demonstrate the bone structure at time of the first investigation. Thickness of external and internal layers of the bone correspond to that of the adjacent areas. The spongy structure has increased hyperdensity beneath the glass abut-

ment system than of the neighbourhood, that means a higher mineral matter content. The next figures (Figures 16-19) show the bone structure at time of the second investigation. There is no change in thickness of both external and internal layers, spongy structure has an increased density compared to the neighbouring areas (A - arc in sqmm, M - density in Hounsfield units).

ture under the glass abutment system.

Conclusion: During this 3 years period no resorption occurred in the bone struc-

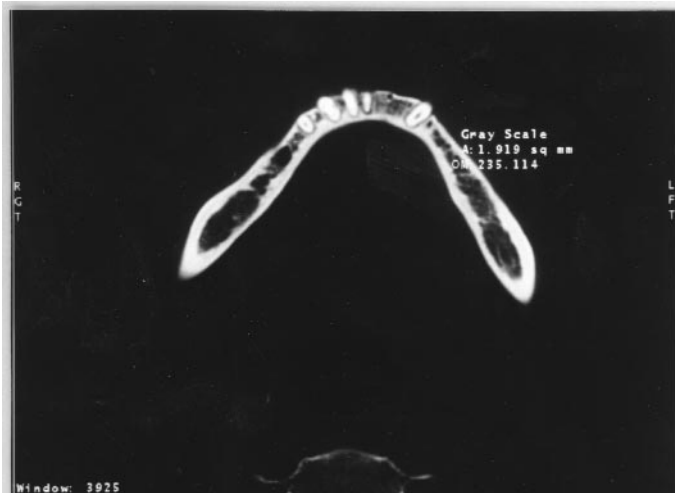

Figure 16. Value of mandible's calcium content immediately in front of the glass abutment on the left, at time of the second investigation, 4 years after oral implantation.

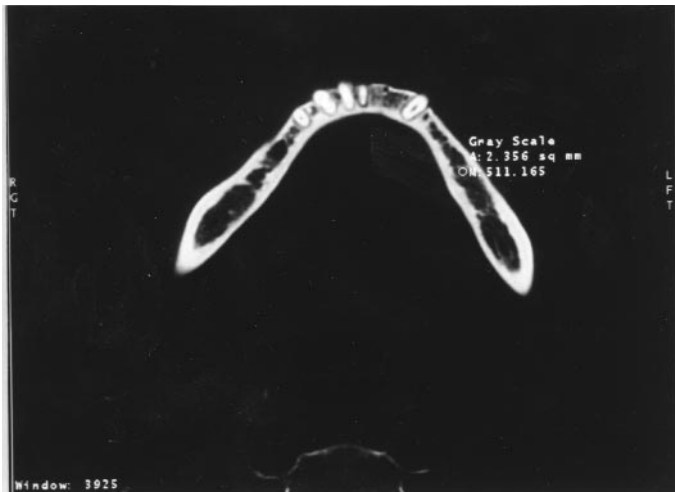

Figure 17. Value of mandible's calcium content under the glass abutment on the left, at time of the second investigation, 4 years after oral implantation.

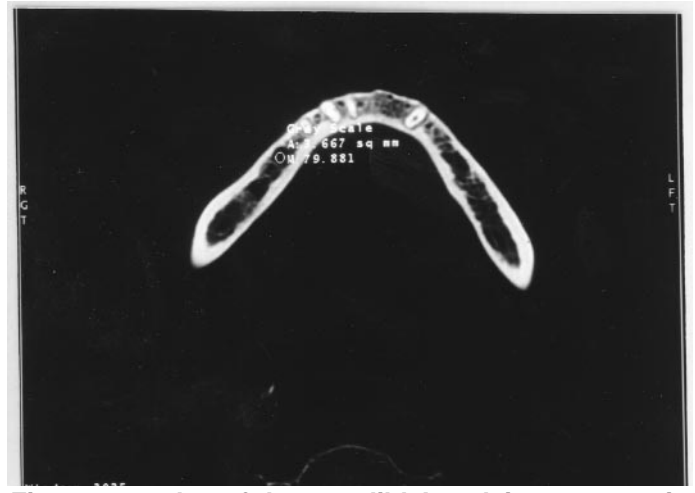

Figure 18. value of the mandible's calcium content in front of the glass abutment on the right, at time of the second investigation, 4 years after oral implantation.

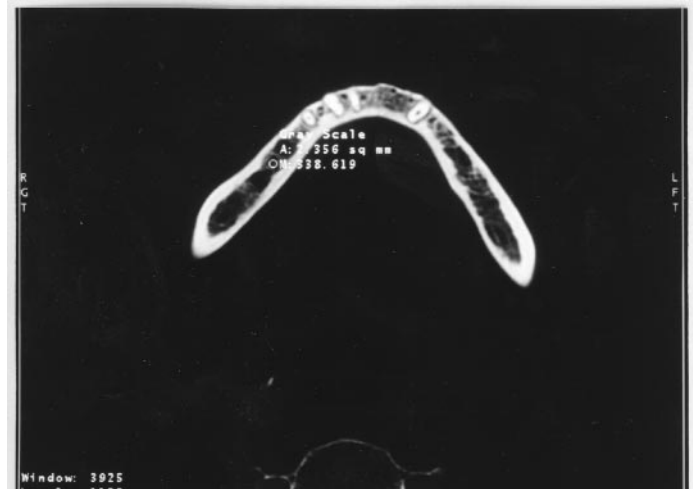


Figure 19. value of the mandible's calcium content under the glass abutment on the right, at time of the second investigation, 4 years after oral implantation.

Description of the employed ZX-27 Attractive Glass Abutment System

Utilization of the dental glass is modern only in its new form. That is why we laid special stress on technological training. Glass abutment can be purchased in prefabricated, semi finished condition (Figure 20.). After unpacking the status corresponding ("S" small, "L" large) glass abutment is inserted into the clamping apparatus (Figure 21.). The melting

flame should be set in that the required melting temperature was around 1560-1600 °C. Be aware that the flame should not be too high because the glass could be boiled (Figure 22.). During melting, care must be taken on finishing the heating of the abutment after the outlines had disappeared as it can be easily boiled with consequent loss of tensile strength

and development of porosity. Thereafter the melted glass will be pressed on secondary model with increasing force (about 0.8 N) (Figure 23.).

Then the glass abutment has to be unstressed again that the remaining potential at time of processing would not cause problems during implantation. It can be best reached with insertion into ceramic bed. Wait until the glass cools below 450 oC. When it cooled, polishing can be started with the use of a diamond polishing equipment run-

ning at 10-15000 r.p.m. At this action care must be taken on the motor not to spin too much and the manufactured equipment not to be hardly pressed onto the abutment as hair cracks can develop due to the friction and heating (Figure 24.). This can lead to fracture of the glass abutment (Figure 24.).

After formation of adequate size compliance with antagonistic and existing supporting teeth, glass abutment has to be controlled on the model. If any kind of inaccuracy present-



Figure 20. Glass abutment can be purchased in two different sizes, "S" and "L" in five and ten pieces of shipment.

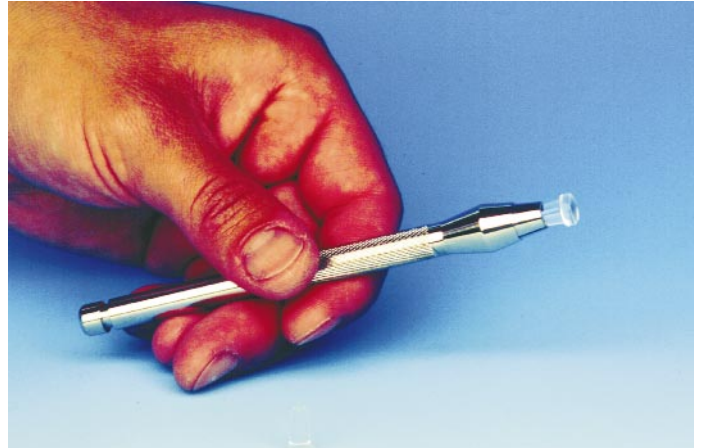

Figure 21. Selection of status corresponding glass sizes and insertion into the clamping apparatus.



Figure 22. Heating of the glass abutment until it be red and its outlines begin to deform.



Figure 23. Heated and melted glass abutment is pressed by continuously increasing 0.8 N force onto the marked place. We wait until it is solidified then put into ceramic cooling coverlet.

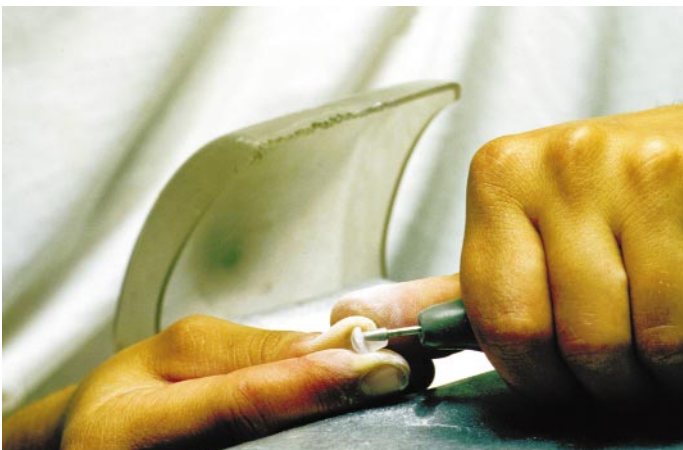

Figure 24. Polishing of the glass with the help of diamond processing equipment.

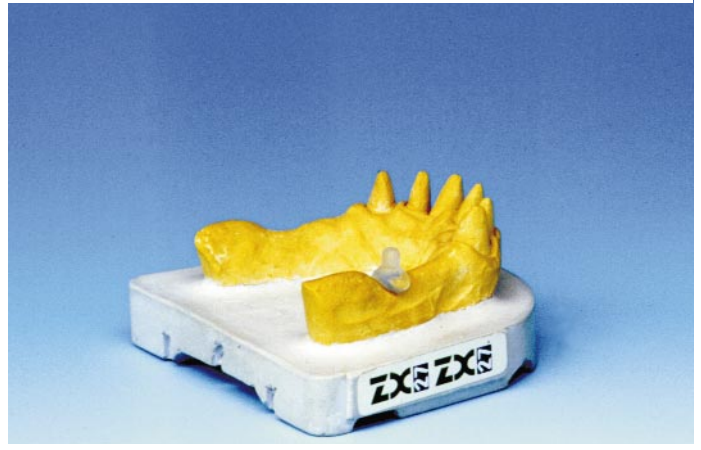

Figure 25. saddle-like accurate adjustment of the glass abutment to the plaster cast.

ted during the process, the glass abutment would not fit saddle-like onto the plaster cast as seen in the picture (Figure 25.). After controlling the position of

the glass, the abutment will be wax immersed (Figure 26.) and the crown will be modeled to the employed cover. When the wax cap is done, the glass abut-

ment will be fixed on the model with the help of hot cervical wax (Figure 27.).If the hot wax ran under the glass abutment, our previous work should be cont-

rolled. This indicates the incorrect position of the glass abutment or the inversion of vestibular-oral part. If we find everything in order the work can be



Figure 26. Formation of wax cap on the glass abutment with wax immersion.

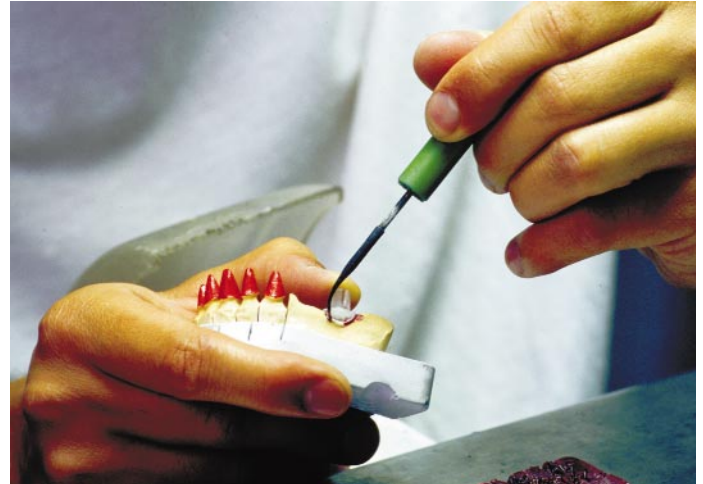

Figure 27. Fixation of the glass abutment onto the model with hot cervical wax.

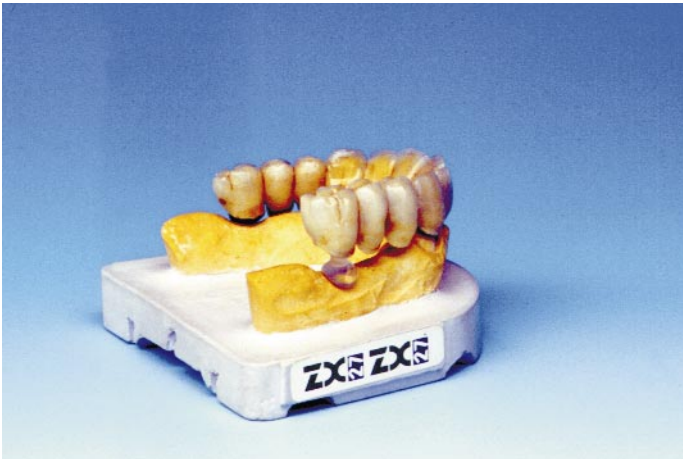


Figure 28. The prepared work and the glass abutment on the cast before sticking.

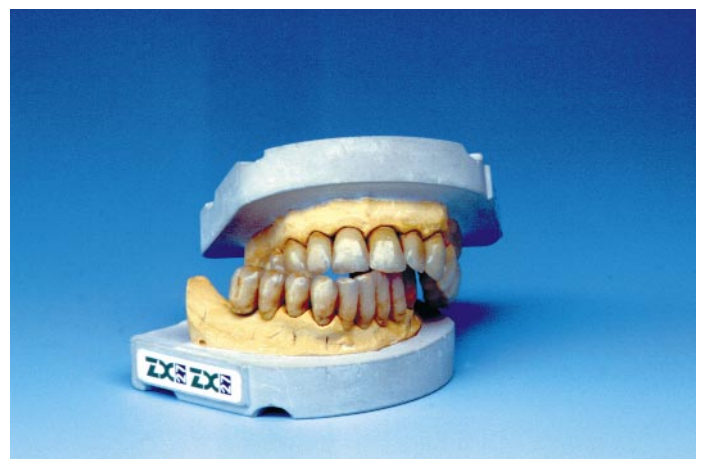


Figure 29. Prepared glass abutment works on the cast.

continued in the traditional way of bridge processing, taking care of a 20% stronger modeling of the bridge work connection from the beginning of the distal-proximal surface of the last supporting tooth to protect the cover. After the preparation of the bridge frame, the ceramic or other coverings should be performed according to the cover technological regulations (Figure 28.). At the end of the process the accurate sticking of the glass abutment is very important. Sticking is performed in the consulting room with the use of phosphate or carboxylate cement in two steps.

First the glass abutment is stuck that is followed by a complete bridge construction in the second step. At time of glass abutment's sticking care must be taken to notice anemic changes due to a slight pressure force during oral implantation, that should disappear within a few minutes. If this manifestation permanently remains, that indicates an incorrect position of the glass abutment on the gum therefore it continuously presses the gum resulting in a consequent bone resorption. At the same time if no anemic change is noticed, then the glass abutment is not in

contact with the gum that is complicated by loosening and loss of the supporting teeth. The well processed work can be seen on Figure 28. It can be noticed that the glass abutment is invisible therefore it suits the esthetic acceptance maximally. The pictures taken on the patients (Figures 29-32). demonstrate well the position and importance of the glass abutment in use. I have met many questions raised during the last 10 years that questioned the applicability. But all questions were based on hypothesis and not on scientifically established background work. Nobody

has thought of searching the materialistic philosophy, the fact, that our faith in infinitude of the universe could help us in reconsidering our previously earned knowledge. Hippocratic oath not only obliges to cure but to thinking and to cooperate with the patients. However the patients have not been asked for a long time. On the recommendation of a professor at the University of Munster, by whom the patients' opinion on the usage of glass abutment can not be indispensable for the clinical and statistical data, we performed a patient contentment

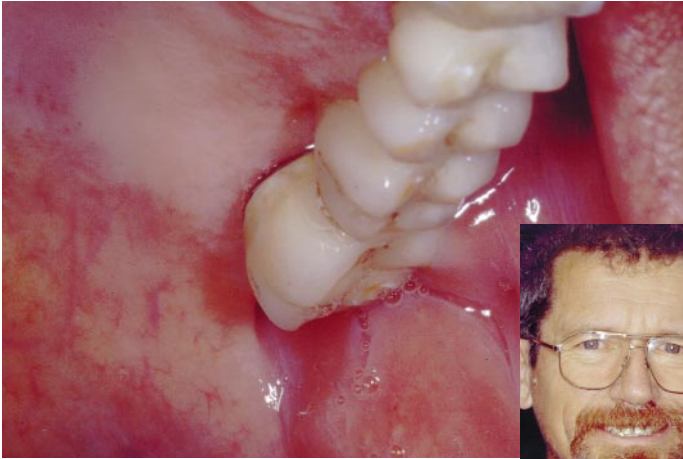


Figure 30. ZX-27 Attractive Glass Abutment under the left upper 7, one year after sticking.

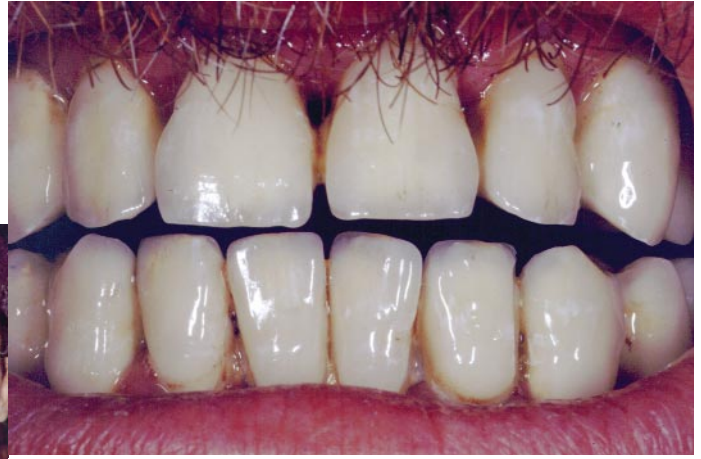

Figure 31. resorting of free end situations with ZX-27 Attractive Glass Abutment System, one year after the sticking.

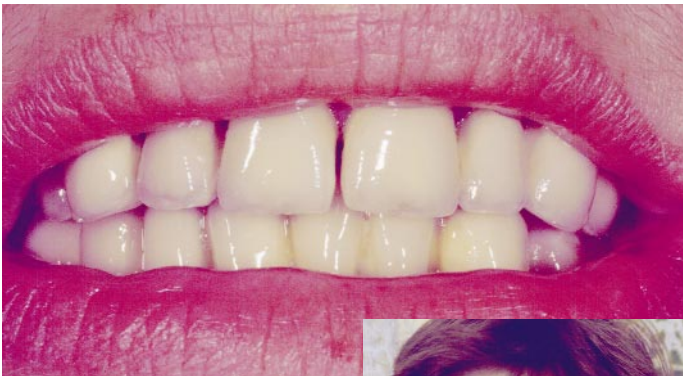

Figure 32. Lower glass abutment circle bridge (CT scan figures 12-19) applied in a patient with diabetes and asthma, for whom neither implant nor removable partial denture could have been manufactured.

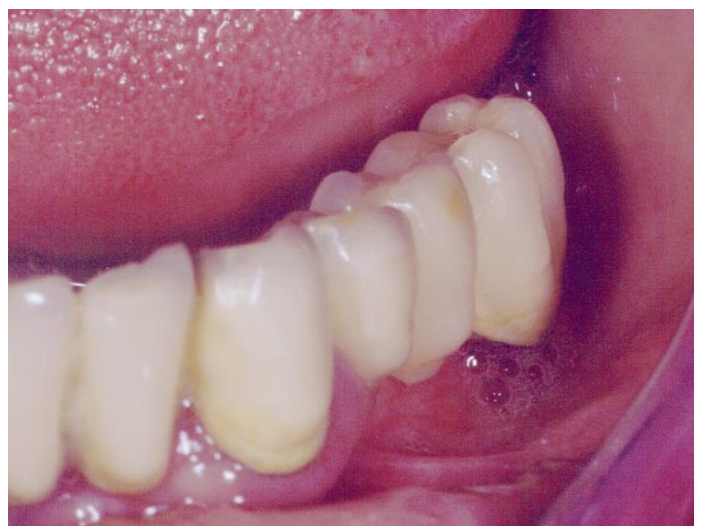
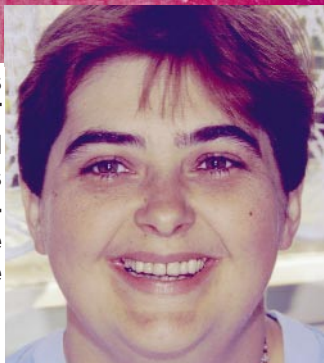
Figure 33. Circle bridge prepared with lower ZX-27 Attractive Glass Abutment System, expanded from six-to-six, the glass abutment is under the sixths, three years after the sticking.

follow-up test. 64% back report arrived to the indirectly posted anonymous questionnaire, that means that 77 of 120 asked patients sent the answers back and the result was 100% following the analysis. Amongst the asked patients we received reports on works having been implanted from 3 months to 10 years, that gave an overall cross section of our labor. As in medical science everything happens for the patients, their comments can

not be ignored. Finally lets stand two opinions here from the 120 questioned patients that also represent the opinion of their ill mates.

„If it depended on me this invention would be lights after the 7 wonder of the world. As this is really a wonder that even at time of sticking I didn't feel the presence of a foreign substance in my mouth. Indeed I had a feeling of my own teeth outgrowing. I can eat everything normally, it doesn't hurt my

gums which were previously sensitive with frequent bleeding and atrophy. But such has not happened and atrophy has stopped since I have been using ZX-27. I believe that the feeling of my own teeth outgrowing says everything about ZX-27. I respect and admire the inventor.“ (Figure 33.)

„I find the glass abutment denture a very good investment. I never accustomed to those inconvenient, unaesthetic denture (I

threw away two of them in five years). I could use the glass abutmental denture immediately, it fits massively to the gum, I chew everything without a problem and of course it's not strange: just like my teeth outgrew. During the last three years of usage, I hadn't even thought about them, until You asked. Congratulations to László Németh and his colleagues.“ (Figure 34.)

